



**Society of Radiologists in Ultrasound  
2012 Toshiba Residents Program**

Kristin K. Porter, MD, PhD  
Johns Hopkins Hospital  
Baltimore, MD

**Clinical History:**

A sixty-seven-year-old woman with unremarkable past medical history presents with alopecia of two to three years' duration, hirsutism with increasing hair growth over her breasts and abdomen, voice changes, and increased libido.

The patient's testosterone was elevated to the low male region of 200s-300s nanograms per deciliter (normal < 43.2 ng/dL) [1]. CT examination of the abdomen and pelvis with intravenous contrast employing an adrenal lesion protocol demonstrated enlargement of the left adrenal gland with a small 6 mm enhancing nodule. No abnormalities of the adnexae were originally detected on CT examination.

The patient underwent ovarian and adrenal vein sampling for testosterone. Most of her values were between 111 and 441 nanograms per deciliter; the only exception was from the right ovarian vein with two samples of greater than 1600 nanograms per deciliter. While there is no consensus regarding the testosterone gradient that localizes the androgen source in adrenal and ovarian venous sampling [1], the marked difference from the right ovarian sample in this case prompted further evaluation with ultrasound. Transabdominal and endovaginal ultrasound examination of the pelvis was performed to evaluate for a testosterone secreting tumor.

**Figures:**

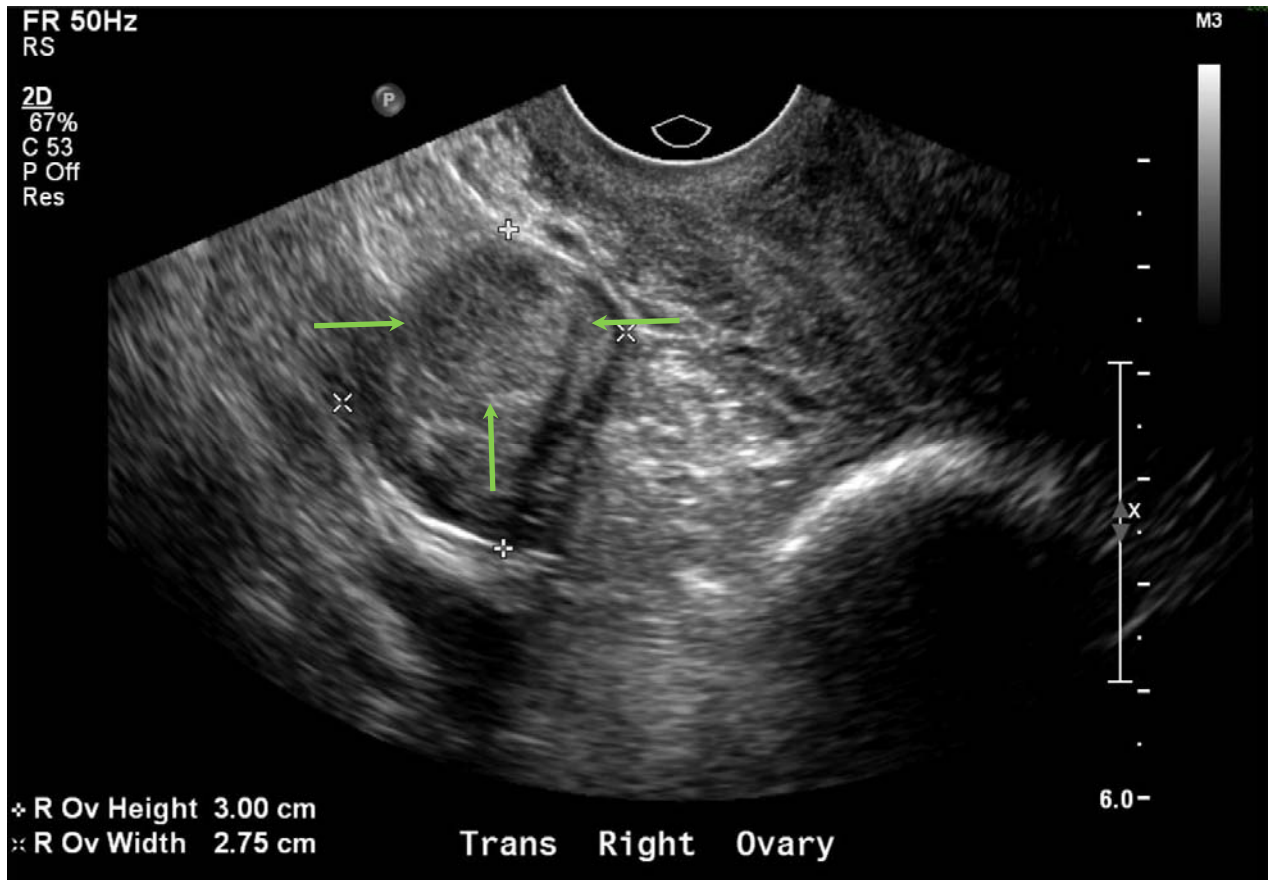


Figure 1. Endovaginal transverse grayscale ultrasound image of the right ovary, which is normal in size and measures 2.6 x 3.2 x 2.7 cm. The right ovary displays no contour abnormality and contains a distinctly seen well-circumscribed, homogeneously echogenic solid mass (indicated by the green arrows).

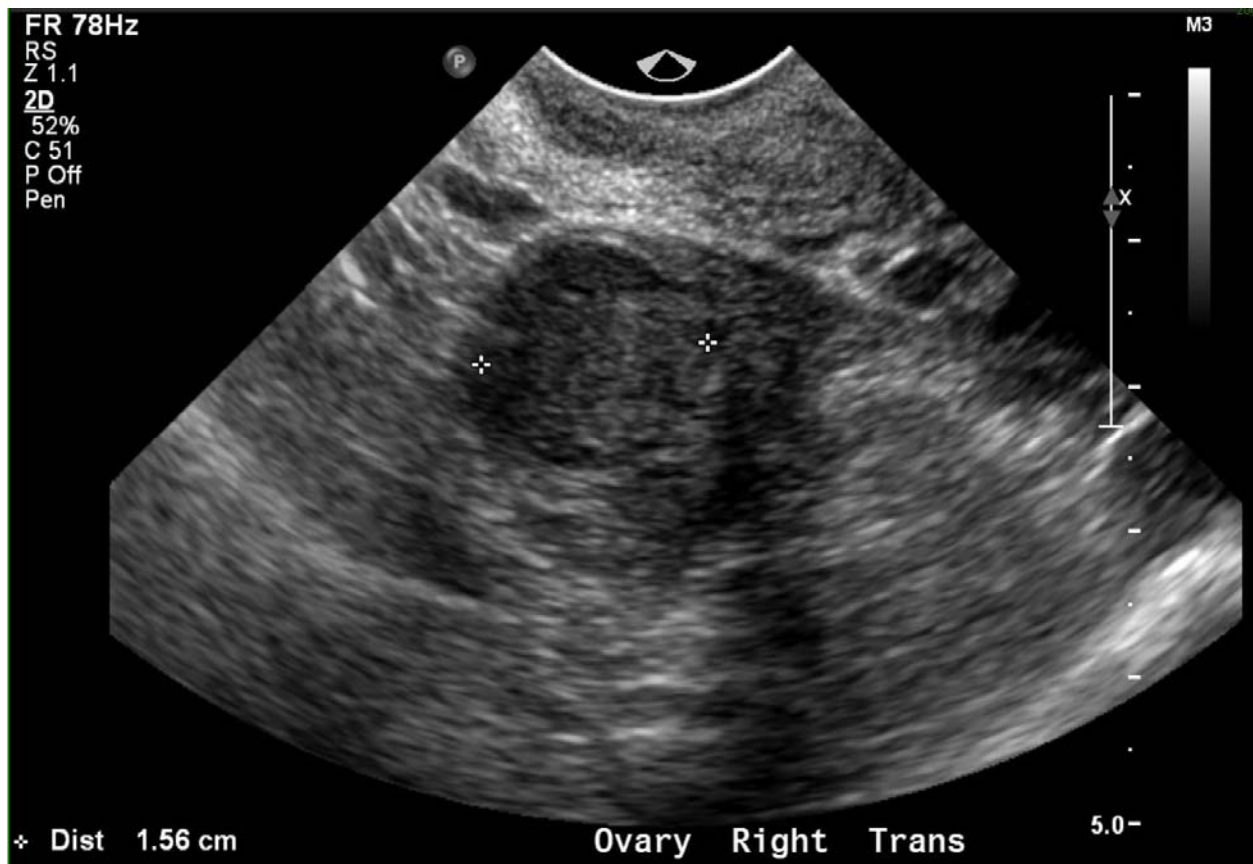


Figure 2. Endovaginal transverse grayscale ultrasound image of the homogeneously echogenic, solid mass in the right ovary, which measures 2.3 x 1.5 x 1.6 cm (between calipers) and does not enlarge the right ovary or alter its external contour.

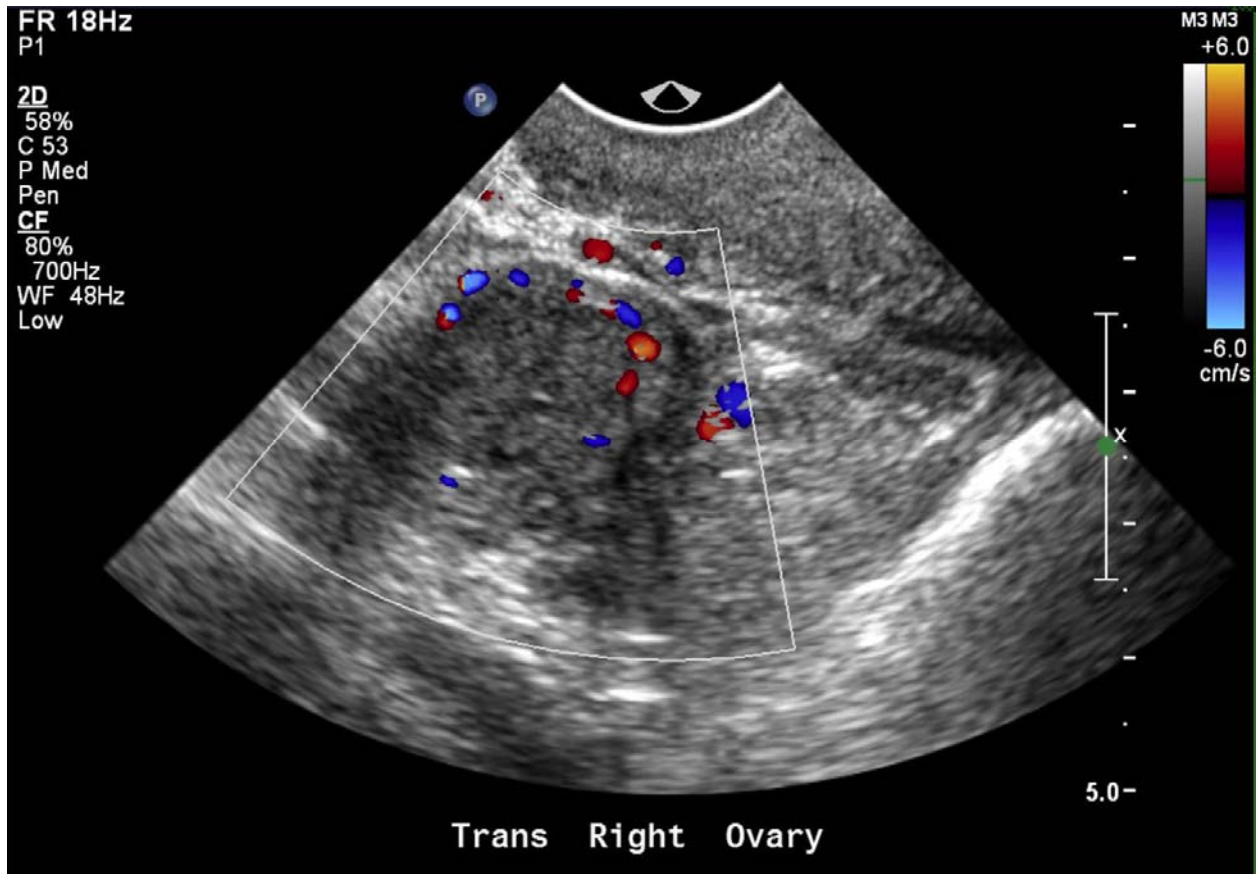


Figure 3. Endovaginal transverse grayscale ultrasound image with color Doppler of the right ovary shows increased intratumoral blood flow within the right ovarian mass. The right ovary was not tender to transducer palpation.

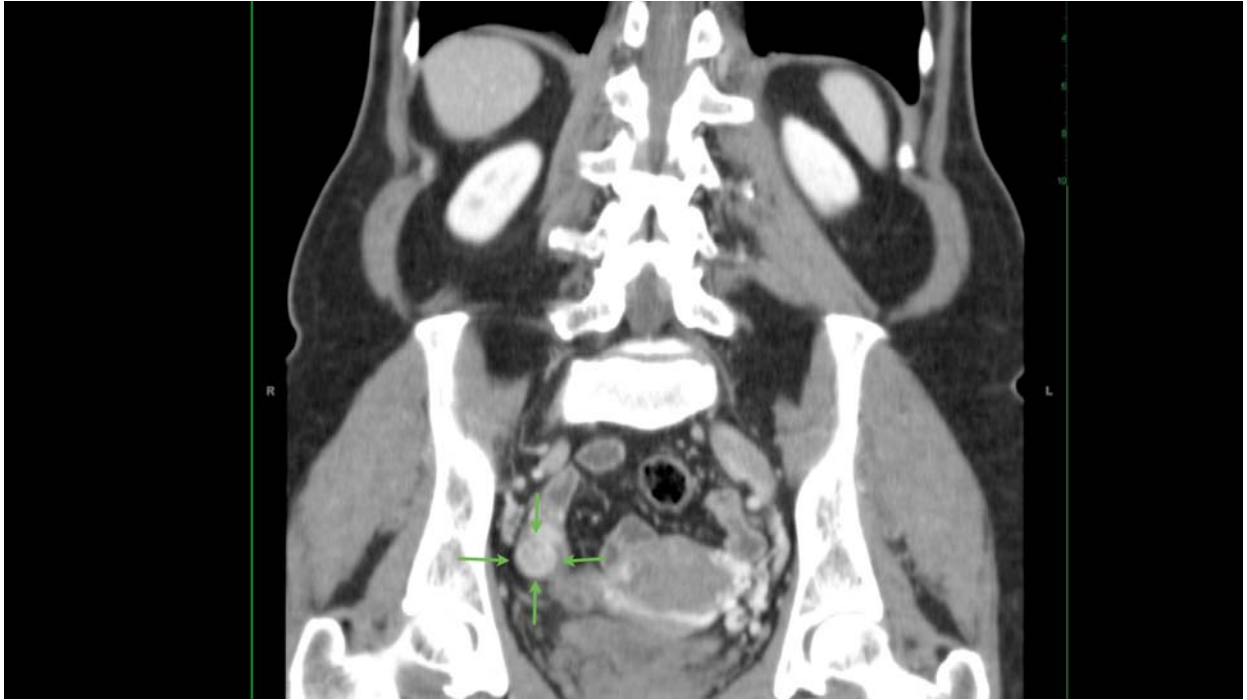


Figure 4. Coronal CT image from the patient's original contrast enhanced CT examination following an adrenal lesion protocol. The solid ovarian mass seen on endovaginal ultrasound examination corresponds to an enhancing mass in the right ovary, measuring 1.6 cm in transverse dimension, indicated by the green arrows.

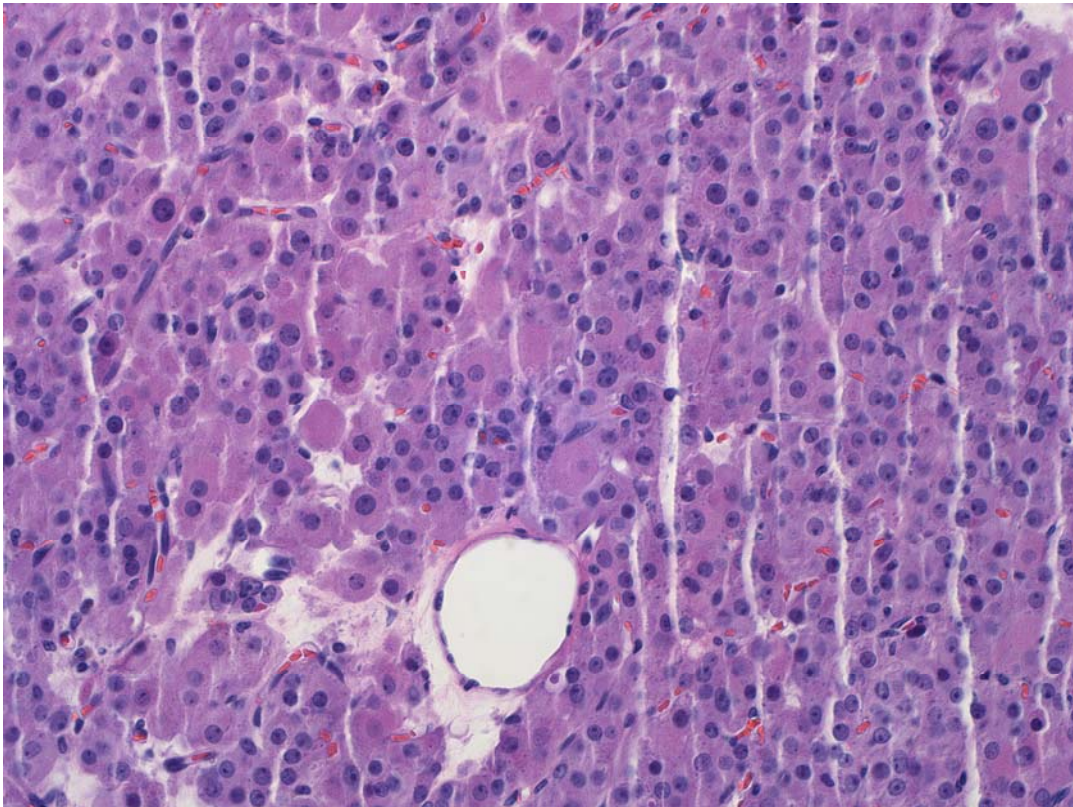


Figure 5. High-power photomicrograph (original magnification  $\times 100$ ; hematoxylin-eosin stain) of the right ovarian tumor shows large cells with abundant eosinophilic cytoplasm with round nuclei. Immunostains for Inhibin, Calretinin, and CD56 were positive, consistent with the diagnosis of steroid cell tumor. On gross examination, the surface of the right ovary was smooth and intact. The right ovary contained a tumor measuring 3 x 3 x 2 cm, which was a variegated tan and brown, well-circumscribed, lobular mass with a thin rim of potentially normal ovary surrounding it.

Diagnosis:

Right ovarian steroid cell tumor (not otherwise specified).

Discussion:

Primary ovarian neoplasms can be subdivided into three general categories: epithelial, germ cell, and sex cord-stromal tumors [2]. Sex cord-stromal tumors account for 5% of ovarian tumors and 2% of malignant ovarian tumors [3]. In contradistinction to the more common epithelial neoplasms, sex cord-stromal tumors have benign or low grade behavior, are often associated with tumor-mediated hormonal effects, and the prognosis is generally good [4].

Ovarian sex cord-stromal neoplasms arise from the dividing cells that would normally become the gonadal stroma surrounding the oocytes. As such, sex cord-stromal neoplasms demonstrate at least some areas with morphology compatible with gonadal stromal differentiation, such as granulosa, theca, Sertoli or Leydig cell types. Ovarian sex cord-stromal neoplasms are subdivided based on their dominant histology; for example, Sertoli stromal tumors, Granulosa stromal tumors, and steroid cell tumors, among others [2].

Steroid cell tumors are composed of cells resembling typical steroid-secreting cells (lutein cells, Leydig cells, and adrenocortical cells) and are further subdivided into: stromal luteoma, Leydig cell tumor, and steroid cell tumor not otherwise specified. Steroid cell tumors account for 0.1%-0.2% of all ovarian tumors and steroid cell tumor not otherwise specified (NOS) is the most common steroid cell tumor category, accounting for 60% of steroid cell tumors. Steroid cell tumors affect women in a wide age range; however, the average age at diagnosis of steroid cell tumors is between the fifth and sixth decade [2]. 25–45% of steroid cell tumors NOS are clinically malignant with metastases typically to the peritoneal cavity, whereas steroid cell tumors in the other two categories are considered benign [3, 4].

The majority of steroid cell tumors NOS are virilizing (56-77%) [6]; therefore, patients may present clinically with androgenic changes, including deepening of the voice, hirsutism, and clitoromegaly. Steroid cell tumors NOS have also been associated with excess estrogen production and Cushing's syndrome [3]. In these patients, appropriate hormonal testing should be performed. Of note, a plasma testosterone of greater than 216 ng/dL almost always arises from an androgen secreting tumor, while a testosterone  $< 86$  ng/dL is unlikely to be related to tumor origin [1]. Approximately 25% of steroid tumors NOS do not demonstrate endocrine or paraendo-

crine manifestations [3]. Women with a suspected steroid cell tumor should undergo pelvic ultrasonography, which remains the imaging modality most frequently used to detect and characterize adnexal masses.

Steroid cell tumors are typically small (<3 cm) and present as unilateral solid tumors [2]. Even though the steroid tumors are small, they are typically well demarcated by different (typically increased) echogenicity using gray-scale ultrasonography and demonstrate increased vascular flow using color Doppler evaluation [3]. Steroid cell tumors may be distinguished from non-neoplastic entities, such as clot in a hemorrhagic cyst or endometriomas, by demonstrating that the tumor is solid; for example, by confirming that internal echoes are present, that there is no through-transmission and that there is vascular flow on color Doppler US. In contrast to steroid cell tumors, which are usually uniformly solid, the majority of epithelial ovarian malignancies have a cystic component and are rarely completely solid [7]. Differentiating steroid cell tumors from other completely solid adnexal masses, such as a pedunculated uterine leiomyoma, ovarian fibroma, lymphoma or metastases, is often not possible based on the sonographic appearance. However, pedunculated fibroids often demonstrate streaky shadowing and a vascular pedicle connecting the mass to the uterus and some ovarian fibromas may display marked acoustic shadowing [7]. Moreover, metastases are often partly cystic. Nevertheless, the distinction between steroid cell tumors and other solid tumor does prove more challenging and often requires incorporation of all the clinical, biochemical and imaging data.

Suspected ovarian steroid cell tumors are managed surgically with staging at the time of initial laparotomy. Conservative surgery typically involves a unilateral salpingo-oophorectomy, given the frequency of bilateral involvement (6%) [2, 3]. Pathological distinction includes histology and specific markers. For example, most steroid cell tumors express inhibin and calretinin and do not express epithelial membrane antigen, while ovarian clear cell carcinoma and metastatic renal cell carcinomas do express epithelial membrane antigen [3, 8]. A Periodic acid-Schiff stain can also be used to demonstrate the presence of glycogen in clear cell carcinomas and metastatic renal cell carcinomas, which is absent in steroid cell tumors [8].

While the majority of steroid cell tumors demonstrate benign or low-grade behavior, about 20% of patients with steroid cell tumor NOS develop metastatic lesions. The most accurate predictor of malignancy is two or more mitotic figures per high power field [3, 8]. The majority of malignant tumors are also larger (diameter of 7 cm or more) and contain hemorrhage and necrosis [3, 8].

Although the ultrasonographic imaging findings in this patient were not completely diagnostic of a steroid cell tumor NOS, taken together with the patient's clinical history and elevated testosterone at the time of ovarian vein sampling, the findings were certain enough to prompt surgical intervention with pathology confirming the diagnosis.

#### References:

1. Petersons CJ, Burt MG. The utility of adrenal and ovarian venous sampling in the investigation of androgen-secreting tumours. *Internal Medicine Journal* 2011 41:1a 69-71.

2. Outwater E K, Wagner B J, Mannion C, McLarney J K, and Kim B. Sex cord-stromal and steroid cell tumors of the ovary. *Radiographics* 1998 18:6 1523-1546.
3. Varras M, Vasilakaki T, Skafida E, and Akrivis C. Clinical, ultrasonographic, computed tomography and histopathological manifestations of ovarian steroid cell tumour, not otherwise specified: our experience of a rare case with female virilisation and review of the literature. *Gynecological Endocrinology* 2011 27:6 412-418.
4. Haji A G, Sharma S, Babu M, Vijaykumar D K and Chitrathara K. Androgen secreting steroid cell tumor of the ovary in a young lactating women with acute onset of severe hyperandrogenism: a case report and review of literature. *Journal of Medical Case Reports* 2007, 1:182.
5. Tanaka Y O, Tsunoda H, Kitagawa Y, Ueno T, Yoshikawa H, and Saida Y. Functioning Ovarian Tumors: Direct and Indirect Findings at MR Imaging. *Radiographics* 2004 24:suppl 1 S147-S166.
6. Kim Y T, Kim S W, Yoon B S, et al. An Ovarian Steroid Cell Tumor Causing Virilization and Massive Ascites. *Yonsei Med J.* 2007 48:1 142–146.
7. Brown D, Dudiak D, and Laing F C. Adnexal Masses: US Characterization and Reporting. *Radiology* 2010 254:2 342-354.
8. Mehdi G, Ansari H A, Sherwani R K, Rahman K, and Akhtar N. Ovarian Steroid Cell Tumour: Correlation of Histopathology with Clinicopathologic Features. *Pathology Research International* 2011 1-5.

Authors:

Kristin K. Porter, M.D., Ph.D.

Joel Fradin, M.D.

Ulrike M. Hamper, M.D., M.B.A.

Mentor:

Ulrike M. Hamper, M.D., M.B.A.

Institution:

Johns Hopkins Hospital, Baltimore, Maryland.