

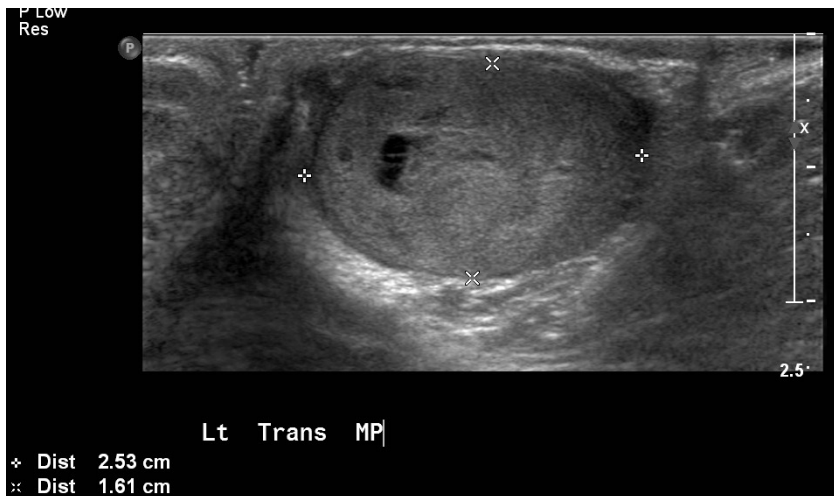


## Society of Radiologists in Ultrasound 2012 Toshiba Residents Program

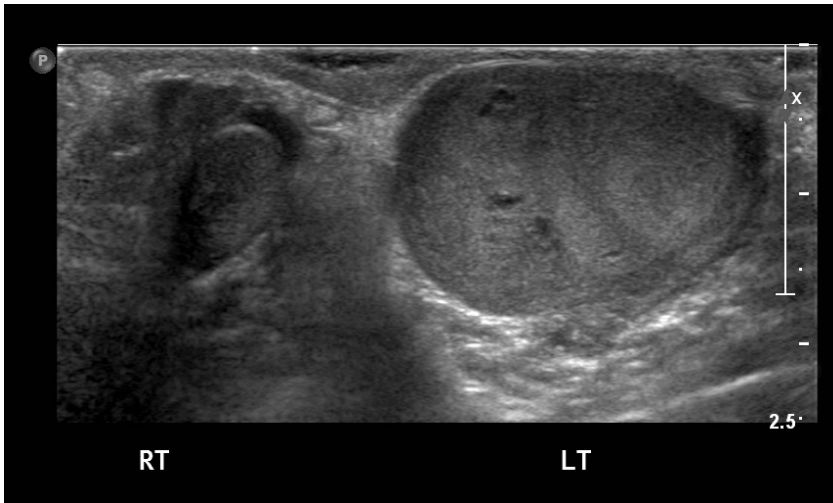
Anita L.Tang, MD  
University of Maryland Medical System

### **Clinical History**

The patient is a 24-month-old African-American male presenting with a two day history of painless left scrotal swelling. The mother denies that the patient experienced any fevers, weight loss, and changes in appetite or energy level. She also reports that both testicles were descended at birth. A scrotal ultrasound was performed and key images are shown in Figures 1 and 2. A chest, abdominal, and pelvic CT demonstrated no additional abnormality. Preoperative serum alpha-fetoprotein (AFP) level was 2.0 ng/mL (normal  $\leq 7.5$  ng/mL) and beta-human chorionic gonadotropin (b-hCG) was  $<1$  mIU/mL (normal 0-3 mIU/mL). The patient underwent a left groin exploration, left inguinal orchiectomy, and excisional biopsy of a retroperitoneal lymph node. Gross surgical specimen is shown in Figure 3 with histologic micrographs in Figure 4. The serum AFP level was 62.2 ng/mL approximately three weeks after surgery and decreased to 10.3 ng/mL at four weeks. A repeat chest, abdominal, and pelvic CT remains negative for metastatic disease.

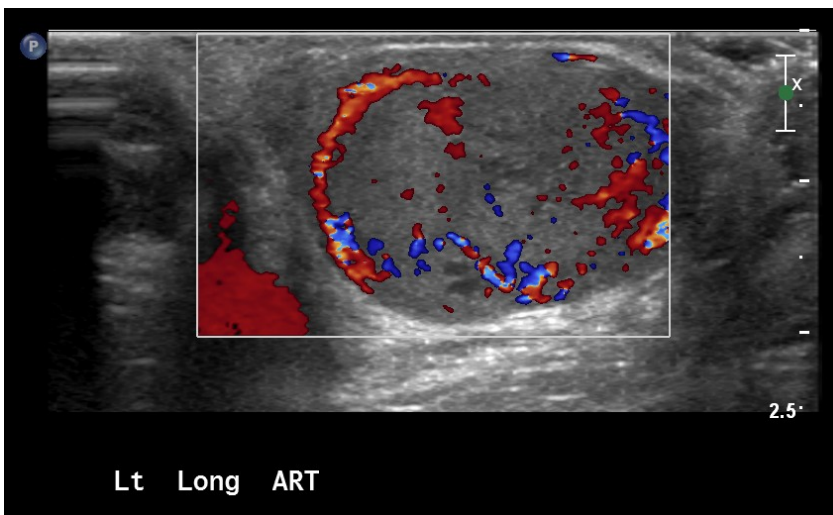


**Figure 1A**

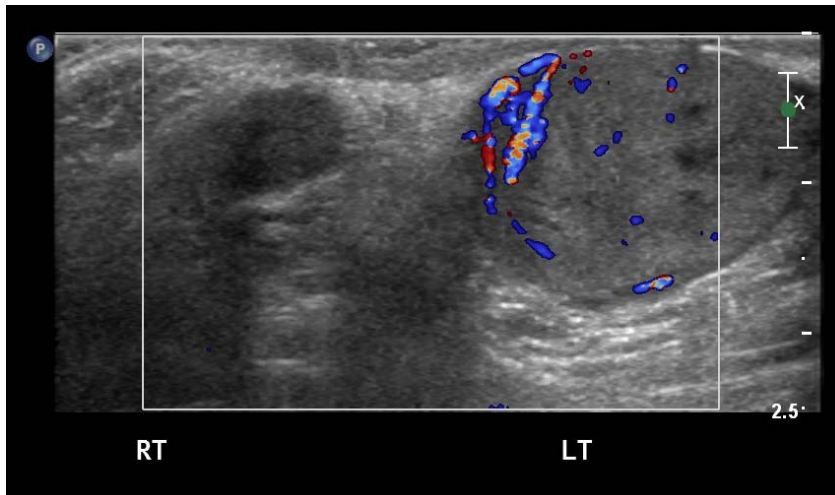


**Figure 1B**

**Figure 1A.** Transverse sonographic view demonstrating a slightly heterogenous, primarily isoechoic multilobulated mass measuring 2.5 x 1.6 cm which nearly completely replaces the left testicle. This mass contains central areas of hypoechogenicity, which may represent foci of necrosis or cystic change. A minimal left hydrocele is present. **B.** Comparison view demonstrating marked enlargement and heterogenous echotexture of the left testicle compared to the normal right testicle. A small right hydrocele is present.

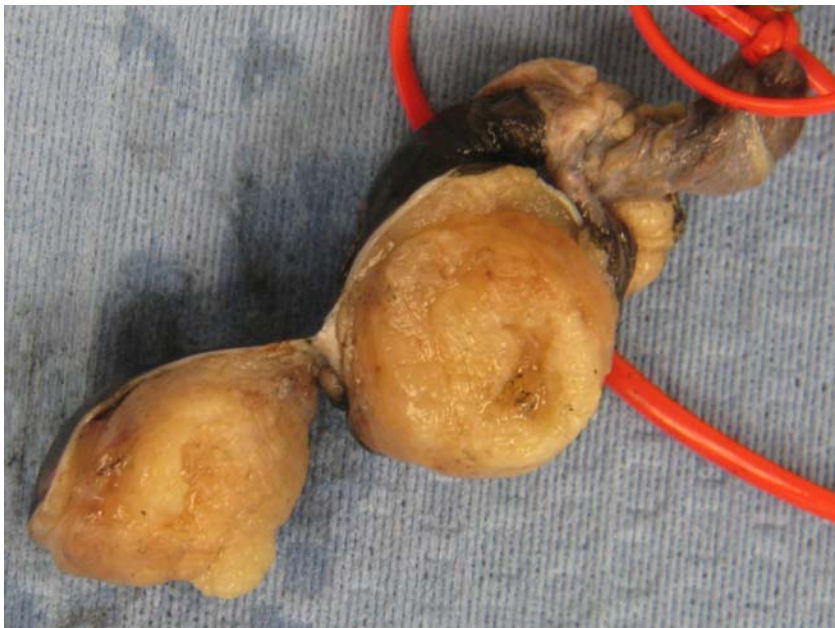

**Figure 2A**



**Figure 2B**

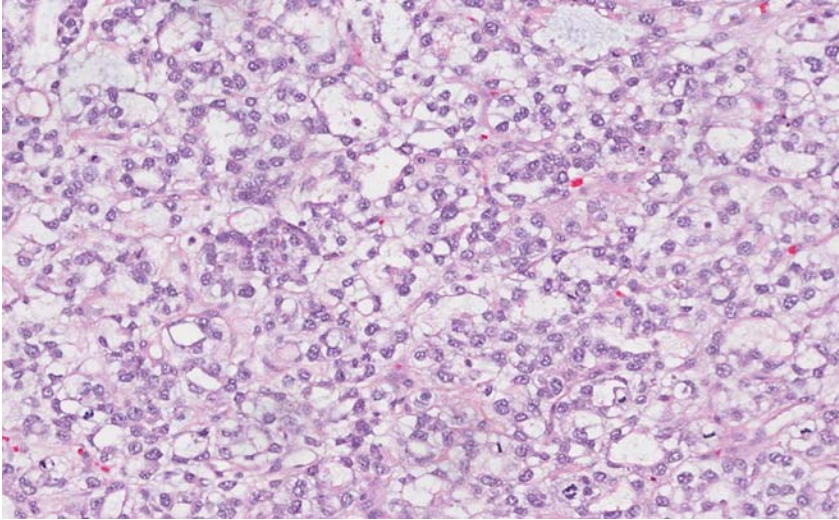
**Figure 2A.** Longitudinal sonographic view demonstrating marked internal and peripheral hypervascularity of the left testicular mass. **B.** Comparison color Doppler view of both testicles demonstrating asymmetric hypervascularity of the left testicle.



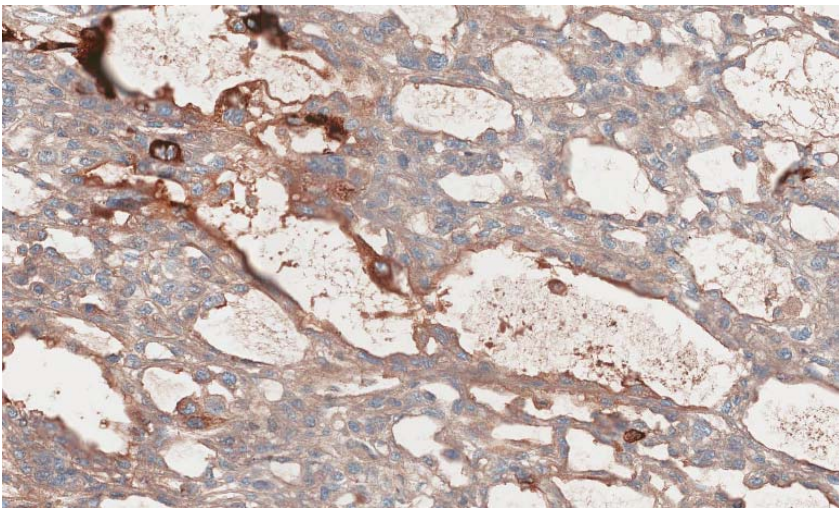
**Figure 3**

**Figure 3.** Gross specimen photograph of the left testicle. Cut surface of the left testicle reveals a lobulated, slightly firm yellow-tan, solid mass measuring 2.0 x 1.7 x 1.7 cm. The mass is confined to the testis and does not extend to the epididymis or through the tunica albuginea. The retroperitoneal excisional lymph node biopsy was negative for malignancy.





**Figure 4A**



**Figure 4B**

**Figure 4A.** High power micrograph (40x) shows a reticular-microcystic pattern. No Schiller-Duval bodies are identified. **B.** Immunohistochemical staining demonstrates positive cytoplasmic staining for AFP. The specimen also stained positively for placental-like alkaline phosphatase (PLAP), CD10, and negatively for b-hCG and CD30 (not shown).

### **Diagnosis**

Yolk sac tumor (endodermal sinus tumor)

### **Discussion**

Testicular neoplasms are uncommon in both children and adults, comprising approximately 1-2% of all neoplasms during childhood and 1% in adults [1-3]. Pure yolk sac tumors almost always occur in children and is the

most common childhood testicular tumor, accounting for 70-80% of malignant testicular neoplasms [1,4]. In contrast, yolk sac tumors in adults rarely occur in isolation and usually present as a component of a mixed germ cell tumor [3]. As prognosis is dependent on early detection and treatment, early diagnosis is of utmost importance.

Pediatric patients usually present with asymptomatic testicular enlargement at a median age of 16 months with a high percentage (80%) presenting early (stage I) in the disease process [2,5]. Evaluation of a solid testicular mass includes scrotal ultrasound, chest, abdominal and pelvic CT, and determination of serum tumor marker levels such as AFP and b-HCG. An elevated AFP level is closely associated with yolk sac tumors in >90% of patients [2,3]. Elevated serum AFP levels may also be found in mixed germ cell tumors containing a yolk sac component, certain teratomas, and infants <6 months of age as AFP is physiologically produced by the fetal yolk sac [1,3].

Sonography is the ideal imaging modality to evaluate testicular pathology. However, the sonographic features of testicular yolk sac tumors are nonspecific, making it difficult to differentiate yolk sac tumors from other solid testicular neoplasms. In many cases, an enlarged inhomogeneous testicle is identified in the absence of a discrete mass [2]. Cystic foci and echogenic foci representing areas of hemorrhage have also been reported [1,7]. Yolk sac tumors also demonstrate increased vascularity compared to normal testicular parenchyma [1]. Additionally, hydroceles have been reported in 15-25% of patients [1].

Yolk sac tumors appear white-gray or tan on gross specimen and are characterized by a number of histological patterns, with the reticular-microcystic subtype being the most common [6]. The Schiller-Duval body, a papillary structure lined by malignant cells and containing a central vessel, is pathognomonic for yolk sac tumor but present in only 50% of cases [4,6]. Immunohistochemical staining for AFP, SALL4 (a stem cell marker), PLAP, and glypian-3 is also performed [6].

The prognosis and treatment of yolk sac tumors is dependent on tumor stage and patient age as 80% of pediatric patients present in stage I versus only 35% of adult patients [4,5]. In pediatric patients, close monitoring with no further treatment may be sufficient if the tumor is confined to the testicle and serial AFP levels normalize following radical inguinal orchiectomy [4,5]. An 80% survival rate has been reported in the pediatric population diagnosed with a stage I tumor [1]. In the adult population, a more aggressive treatment protocol is utilized which includes radical orchiectomy, chemotherapy, and retroperitoneal lymph node dissection. The rationale for more aggressive treatment in adult patients include a higher stage at presentation and the tendency to present as a component of a mixed germ cell tumor which is associated with a worse prognosis [4]. Another reason for less aggressive treatment in pediatric patients is the increased likelihood of yolk sac tumors to spread hematogenously in children, making routine retroperitoneal lymph node dissection less useful [4]. Since serum AFP levels are elevated in the vast majority of patients pre-operatively and can be monitored post-operatively to detect recurrence, chemotherapy with or without retroperitoneal lymph node dissection can be

reserved for children with elevated or rising AFP levels and/or retroperitoneal lymphadenopathy. In cases of recurrence or metastasis, the vast majority can be successfully treated with chemotherapy [4].

Our reported case is in concordance with the typical presentation, age, and imaging characteristics reported in the literature. However, it is uncertain why the pre-operative serum AFP level was normal while the post-operative level was elevated; nonetheless, it continues to exhibit a gradual decline suggesting complete cure.

### **References**

1. Xu HX, Yi XP. Sonographic appearance of a testicular yolk sac tumor in a 2-year-old boy. *J Clin Ultrasound*. 2007 35:55-7.
2. Woodward PJ, Sohaey R, O'Donoghue MJ, Green DE. From the archives of the AFIP tumors and tumorlike lesions of the testis: Radiologic-pathologic correlation. *RadioGraphics*. 2002 22:189–216.
3. Bahrami A, Ro JY, Ayala AG. An overview of testicular germ cell tumors. *Arch Pathol Lab Med*. 2007 131:1267-80.
4. Agarwal PK, Palmer JS. Testicular and paratesticular neoplasms in prepubertal males. *J Urol*. 2006 176:875-81.
5. Ross JH, Rybicki L, Kay R. Clinical behavior and a contemporary management algorithm for prepubertal testis tumors: a summary of the Prepubertal Testis Tumor Registry. *J Urol*. 2002 168:1675-8; discussion 1678-9.
6. Cao D, Humphrey PA. Yolk sac tumor of the testis. *J Urol*. 2011 186:1475-6.
7. Gorman B. The Scrotum. In: Rumack CM, (ed.). *Diagnostic Ultrasound* 4th Ed. Philadelphia: Elsevier, 2011:840-877.

### **Authors**

Anita L. Tang, M.D., Sandy Liu, M.D., and Jade J. Wong-You-Cheong, M.D.

### **Mentor**

Jade J. Wong-You-Cheong, M.D.

### **Institution**

University of Maryland Medical Center  
Baltimore, MD